

Adherence To Practice Guidelines For Erector Spinae Plane Block-Catheter Based Analgesia In Thoracic Surgery Patients

Sami Ur Rehman^{*1}, Naila Qamar¹, Aleena Kashif¹, Rabia Basri¹, Unaiza Saeed¹, Eesha Rehman²

¹Department of Anesthesia, Doctors Hospital and Medical Centre, Lahore, Pakistan

²Services Institute of Medical Sciences Lahore, Pakistan

*Corresponding author's email address: sami373rehman@gmail.com

(Received, 24th November 2024, Revised 2nd February 2025, Published 28st February 2025)

Abstract: In thoracic surgery, effective postoperative pain management is crucial to enhance recovery and reduce complications. Erector spinae plane block (ESPB) has gained recognition as a promising regional analgesic technique due to its safety, ease of administration, and minimal complications. However, variations in its utilisation, catheter placement techniques, local anesthetic concentrations, and infusion rates remain an area of clinical interest. **Objective:** This study aims to scrutinise the utilisation of ESPB-catheter based analgesia practice in thoracic surgery patients, techniques, complications and different concentrations and volumes of local anesthetics used for pain relief. **Study design:** Clinical practice article/Clinical Audit. **Study Place and Duration:** 2.5 years from 1st January 2022 to 30th June 2024 in Doctors Hospital and Medical Centre (DHMC) operation theatres, Lahore, Pakistan. **Methodology:** A total of 76 patients were included in the study. All captured data was recorded manually and then presented as frequencies (percentages) in Microsoft Word Office 365 tabulated form. All calculations were done manually. **Results:** 76 erector spinae plane block related catheters were inserted in thoracic surgery patients. Tuohy's needle was used for ESPB. Mean needle depth was 5cm and mean catheter depth was 11cm. Different concentrations of local anesthetics were used (0.1%, 0.2% and 0.25%) at different infusion rates (10ml/hour up to 20ml/hour). No complication was encountered during our study period. **Conclusion:** Erector Spinae Plane Block provides the best pain relief with minimum complication risks and maximum postoperative benefits, including its use in patients with coagulopathy and systemic infections. So, ESPB catheter-based analgesia with continuous infusion (0.15 or 0.2% bupivacaine at 15-20ml/hour) should be the preferred mode of postoperative analgesia after thoracic surgery. The catheter can be kept for a maximum of 6 days. Hence, a collaborative approach is required between the thoracic surgeon and the anesthetist.

Keywords: Erector spinae block, Thoracic surgery, Enhanced recovery after surgery (ERAS) protocol, Video-Assisted Thoracoscopic Surgery (VATS)

[How to Cite: Rehman Su, Qamar N, Kashif A, Basri R, Saeed U, Rehman E. Adherence to practice guidelines for erector spinae plane block-catheter based analgesia in thoracic surgery patients. *Biol. Clin. Sci. Res. J.*, 2025; 6(2): 157-162. doi: <https://doi.org/10.54112/bcsrj.v6i2.1468>

Introduction

Thoracic surgery, vital for treating a range of pulmonary and mediastinal conditions, is often accompanied by intense postoperative pain, presenting a significant challenge in patient care. Inadequate pain management following thoracic procedures not only compromises patient comfort but also leads to prolonged hospital stays and increased risk of complications, including respiratory issues, impaired wound healing, and the development of chronic pain syndrome (1). Consequently, there's a pressing need to enhance pain management strategies to improve postoperative outcomes and patient satisfaction in thoracic surgery settings.

The erector spinae muscle group comprises a series of muscles running parallel to the spine, extending from the sacrum to the base of the skull, that play a crucial role in maintaining posture and controlling spinal movement. Anatomically, the erector spinae muscle group is situated laterally to the vertebral column, making it accessible for regional anesthesia techniques such as ESPB (2).

One promising approach that has garnered attention for addressing post-thoracotomy pain is the erector spinae plane block (ESPB). This technique involves the targeted deposition of local anesthetic in the myofascial plane between the erector spinae muscle and transverse processes (3). By utilising the anatomy of the erector spinae muscle group and its proximity to the vertebral column, ESPB offers a potential solution for adequate analgesia in thoracic surgery. The ESPB has the advantage of being considered even in coagulation abnormalities, as the injection site is distant from the nerve bundle, major blood vessels, and pleura(4).

The ESPB reduces the opioids consumption postoperatively and hence complementing the Enhanced Recovery after Surgery (ERAS) protocols (5, 6).

Recent studies have provided promising evidence regarding the efficacy of ESPB in thoracic surgery. For instance, a systematic review by Forero et al. (7) reported favorable outcomes in terms of pain relief and opioid-sparing effects following ESB in various thoracic surgical procedures. The site of action is ventral and dorsal rami of thoracic spinal nerves extending from T3 to T10 (7). Additionally, Blanco et al. (2020) conducted a randomised controlled trial comparing ESB with conventional analgesic techniques, demonstrating superior pain control and reduced opioid consumption in the ESB group (8). Different randomised controlled trails regarding the efficacy of ESPB analgesia have been done (9-11).

The investigation into the analgesic efficacy and safety of erector spinae block in thoracic surgery represents a crucial area of research to optimise postoperative pain management. Leveraging the anatomical accessibility and nerve-blocking properties of the erector spinae muscle group, ESB holds promise as an adjunct to traditional analgesic modalities (12). However, further research is warranted to delineate optimal techniques, dosing regimens, and patient selection criteria to maximise the benefits of ESB while minimising risks. Establishing the role of ESB in thoracic surgery analgesia has the potential to enhance patient outcomes, reduce opioid consumption, and improve overall perioperative care.

This study aims to scrutinise the utilisation of ESPB-catheter based analgesia practice in thoracic surgery patients, techniques, complications



and different concentrations and volumes of local anesthetics used for pain relief.

Methodology

This is a cross-sectional study, and data were collected retrospectively over 2.5 years from 1st January 2022 to 30th June 2024 in the Operation theaters of Doctors Hospital and Medical Centre, Lahore, Pakistan. Non-probability consecutive convenience sampling is used to collect the data from the Erector spinae Block related catheter documentation registers. We have measured the median age of patients, type of surgery, gender, level of insertion, technique, any complications we face, number of days catheter remained in-situ and analgesic efficacy of erector spinae block related catheters. Data was collected from the Erector Spinae Block Register, which was used to save the documented records of all erector spinae blocks used in any surgery. All patients undergoing thoracic surgeries, who had given written consent, at DHMC were included. Exclusion criteria include hypersensitivity to local anesthetics. All captured data was recorded manually and then presented as frequencies (percentages) in Microsoft Word Office 365 tabulated form. All calculations were done manually. The ultrasound-guided ESP block catheter was inserted at the end of the procedure in lobectomy, Pneumonectomy, decortication and thoracotomy. At the same time, ESPB catheter was inserted in pleural

biopsy procedures before the procedure. Patients were made to lie at the edge of the bed in the lateral position while under anesthesia. Depending on the patient's anatomy, a low-frequency probe (4-8 MHz, curvilinear) or high frequency probe (5- 12 MHz) was placed transversely to identify the spinous process. After identifying the spinous process, the probe was moved laterally by 2.5-3cm and rotated 90°, making it in the sagittal orientation to determine the transverse process. In this position, the trapezius, rhomboid major, and erector spinae muscles were determined to confirm correct probe position. A 16G or 18G Tuohy's needle was inserted craniocaudally in plane at the level of T7 or T8 and advanced until it reached the transverse process. The catheter was inserted into the space after the needle position was confirmed using an ultrasound. Usually the catheter is kept 6-7cm above the needle depth. A bolus dose, up to 20-30 ml of 0.25% bupivacaine (2.5-3 mg/kg), was injected into the plane between the erector spinae muscle and the transverse process before the incision and continuous infusion of local anesthetic via the catheter postoperatively. The spread of local anesthetic was checked in the postoperative care unit by injecting iohexidol contrast via the ESPB catheter. The ESP block was deemed successful if the local anesthetic diffused in a linear pattern up to T8-T9 level and the patient developed appropriate sensory loss. See Figure 1 and Figure 2 to get an idea of the sonoanatomy of ESPB.

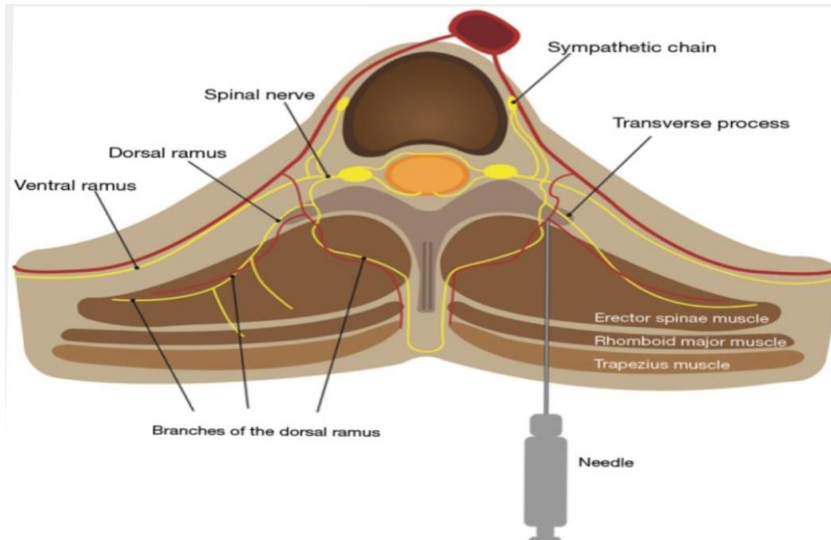


Figure 1: showing the anatomy for erector spinae plane block

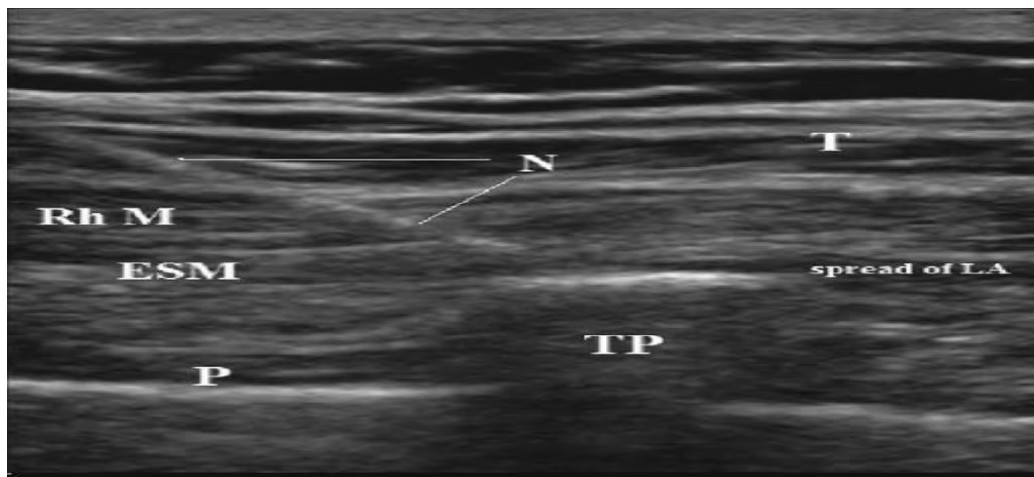

Figure 2: Sono-Anatomy Showing the Inline Technique for Erector Spinae Plane Block. Shows the Sonoanatomy, T= Trapezius, N=Needle, Rhm= Rhomboid Muscle, TP=Transverse Process and P=Plane (Myofascial Plane between Transverse Process

Results

76 erector spinae plane block related catheters were inserted in thoracic surgery patients for postoperative analgesia throughout this study period. Out of 76 patients, 48 were male and 28 were females (see table 1). Median age of patients undergoing these thoracic surgeries is 52 years.

Patient’s demographics are given in Table 1. Most of the thoracic surgeries are Video-Assisted surgeries and the type of thoracic surgery for which ESPB catheters were inserted is shown in table 1. The year-wise distribution of the Erector spinae plane block is shown in Table 2.

Out of the 76 ESPB related catheters, 68 were done ultrasound-guidedly, while eight were blindly via landmark technique. ESPB catheter was inserted in lateral position after induction of anesthesia. Tuohy’s needles were used to insert catheters in the erector spinae plane. 18G Tuohy’s needle was used in 42 patients while 16G Tuohy’s needle was used in 34 patients. Mean needle depth was 5cm and mean catheter depth was 11cm. Usually, the catheter is kept 6 to 8cm above the needle depth. Different concentrations of local anesthetics were used with 0.1% concentration in 41 patients followed by 13 (0.15% concentration), 9 (0.2% concentration) and 5 (0.25% concentration). Our study used Bupivacaine and ropivacaine for ESPB depending on the preference of the consultant performing the procedure. Bupivacaine was used in 58 patients and ropivacaine was used in 18

patients. Adjuvants used along with Bupivacaine or Ropivacaine were fentanyl (4 patients), and dexmedetomidine (5 patients). Infusion volumes used were 10ml/hour in 15 patients, 15ml/hour in 22 patients and 20ml/hour in 33 patients (see table 3).

Table 3: Shows the features of Erector Spinae Plane Block, including the technique used, Position of patient, needle used, catheter depth, different concentrations used and adjuvants used via Erector Spinae Plane Block catheters

The most number of catheters were removed on day 3 (27.6%), followed by day 2 (23.6%), day 4 (21%) and day 1 (18%), see table 4. Complications (table 5) related to ESPB were accidental removal in 10 patients (13%) and one patient had leakage from catheter site (1.3%).

Among the 76 patients in Table 6, 69 (90.7%) were shifted toward or to the room, 7 (9.2%) were moved to the Intensive Care Unit. Out of the seven patients who were turned to the Intensive Care Unit, two expired due to surgical complications.

Visual Analogue score (VAS) compares the efficacy and the best concentration of local anesthetic to be used as infusion via ESPB catheter, see table 7. VAS score zero is given as no pain and 10 as unbearable pain. Paracetamol was given three times a day in the treatment chart and intravenous tramadol was given whenever the VAS score exceeded four while coughing.

Volume via ESPB was also compared by seeing the VAS score, see Table 8.

Table 1: Shows the demographics of patients and the type of surgery

Demographics	Number	Percentage
Gender		
Male	48	63.1%
Female	28	36.8%
Procedure		
VATS (Biopsy)	6	7.89%
VATS (Lobectomy)	24	31.5%
VATS (Pneumonectomy)	17	22.3%
VATS (Decortication)	24	31.5%
Open Thoracotomy	1	1.3%
Esophagostomy	4	5.26%

Table 2 shows the year-wise distribution of Erector Spinae Plane Blocks.

Year/Time Frame	Number	Percentage
2022	12	5.7%
2023	41	53.9%
2024 until June	23	30.1%

Table 3:

Level of insertion	Number	Percentage
Technique:		
1. Blind/Landmark	8	10.5%
2. Ultrasound guided	68	89.47%
Position of patient:		
1. Sitting	3	3.94%
2. Lateral	76	100%
Needle used:		
16G	32	42.1%
18G	44	57.89%
Needle depth (median)	5cm	N/A
Catheter fixed at (median)	11cm	N/A
Infusion concentration used:		
1. 0.1% Bupivacaine	43	56.5%
2. 0.125% Bupivacaine	Nil	-

3. 0.15% Bupivacaine	17	22.3%
4. 0.2% Bupivacaine	9	11.84%
5. 0.25% Bupivacaine	5	6.5%
6. No infusion used	4	5.2%
Adjuvants used:		
1. Bupivacaine + fentanyl	2	2.6%
2. Bupivacaine + dexmedetomidine	4	5.2%
3. Ropivacaine + fentanyl	-	-
4. Ropivacaine + dexmedetomidine	2	2.6%
5. No adjuvants used	1	1.3%
	67	88.1%
Infusion volume used:		
1. 10ml/hour	15	19.7%
2. 15ml/hour	22	28.94%
3. 20ml/hour	33	43.42%

Table 4 shows the number of days the catheter was kept in-situ.

Removal of catheter by (Days)	Number	Percentage
• The day of insertion is taken as zero days.		
1	14	18.42%
2	18	23.68%
3	21	27.6%
4	16	21.05%
5	5	6.5%
6	2	2.6%

Table 5: Shows the frequency of complications related to Erector spinae plane block catheter

Complication	Number	Percentage
Catheter fell out	10	13.1%
Leaking from the catheter size	1	1.3%
Technical failure	0	0
Hematoma	0	0
Neurological deficit	0	0

Table 6: Patient destination in the postoperative period.

Destination	Number	Percentage
ICU	5	6.5%
Ward/Room	69	90.7%
Expired	2	2.6%

Table 7: showing VAS score for different concentration and time to first opioid consumption.

Infusion concentration used	No. of patients with this infusion	VAS at 6 hour (mean)	VAS at 12 hour (mean)	VAS at 24 hour (mean)
0.1% Bupivacaine	43	4.7	4.2	3.6
0.125% Bupivacaine	Nil	-	-	-
0.15% Bupivacaine	17	2.2	2.6	1.8
0.2% Bupivacaine	9	1.9	2.3	1.7
0.25% Bupivacaine	5	1.5	1.9	1.5
No infusion used	4	-	-	-

Table 8 shows the correlation between different ESPB and VAS scoring volumes.

Infusion volume used	VAS at 6 hours (mean)	VAS at 12 hours (mean)	VAS at 24 hours (mean)
10 ml/hour	4.8	4.5	4.2
15ml/hour	2.8	2.1	1.8
20ml/hour	2.1	1.8	1.7

Table 9 shows the weight-based dosing of local anesthetics for single shot Erector spinae plane block analgesia.

Drug	50kg patient	70kg patient	100kg patient
Unilateral, 0.25% Bupivacaine, ml	30	40	40
Unilateral, 0.5% Bupivacaine, ml	20	20	30
Bilateral 0.25% Bupivacaine, ml	20 per side (40 total)	25 per side (50 total)	30 per side (60 total)
Bilateral 0.5% Bupivacaine, ml	Not advised, not enough volume	Not advised, not enough volume	Not advised, not enough volume

Discussion

Regional anesthesia techniques have an upper hand on opioid based analgesia regime for postoperative analgesia after thoracic surgeries. Few standard regional anesthesia modalities commonly used are Erector Spinae Plane Block, Epidural Analgesia, Paravertebral block, and intercostal nerve block (13). Erector Spinae Plane Block has an advantage over the remaining regional anesthesia techniques in that it has fewer complications, better pain control, more favorable lung parameters, and less hemodynamic instability.

The mechanism of action of ESPB analgesia is still unclear. Analgesic effect is provided by blocking the posterior branch of thoracic spinal nerve, but also at the paravertebral space by blocking the anterior branch of thoracic spinal nerve and the intercostal nerve, following the cranio-caudal and lateral extension into these nerves (14).

Ultrasound-guided ESPB is always preferred over the landmark technique approach, improving efficiency and reducing the chance of complications and failure rate. This block collectively provides visceral, somatic and sympathetic blockade over the spread territory (15).

ESPB is also considered safe in patients with coagulopathy and with patients on dual antiplatelet drugs or anticoagulants. The target site is away from the pleura, major vessels, nerves, and spinal cord, thus minimising the risk of complications (16, 17).

We use continuous infusion based analgesia via ESPB catheter in our setup for thoracic surgery patients. Thamizarasan et al. (18) concluded that programmed intermittent bolus techniques have better postoperative analgesia than continuous infusion technique. But in the study mentioned above, they have used local anesthesia infusion at a very low volume of 5ml/hour, while the practice in our setup is to infuse the local anesthetic between 15ml/hour to 20ml/hour depending on the analgesia target. Intermittent bolus doses can also be given before chest physiotherapy and mobilisation to mitigate any chances of breakthrough pain from stimulus. Before any such mobilisation, a bolus dose of 20ml, 0.2% to 0.25% bupivacaine or ropivacaine is recommended. Our practice is that the patient remains on continuous infusion of local anesthetic via ESPB catheter for the next 24 hours. Then, after re-evaluation, the patient was shifted to intermittent boluses. All patients were given pregabalin, tapentadol and paracetamol on the day of discontinuation of the continuous infusion regime. Luftig et al. (19) introduced a weight-based dosing regime (see Table 9). Another study by Tonetti et al. (20) says that 3.6ml of volume is required per desired vertebral level in ESPB, but there is no further research into this volume requirement. Our results deduce that for continuous infusions, 0.15% and 0.2% at 15-20ml/hour, both local anesthesia toxicity and analgesic effects should be kept in mind. For bolus doses, we will recommend the regime given by Luftig et al. (19).

On average, the catheter remained in-situ for 2.8 days to a maximum of 6 days. The complication rate in our patients is zero. The primary complications in the literature that can happen include pneumothorax, hemi-diaphragmatic paralysis and other respiratory complications. In a study by Tulgar et al. (21), out of 308 patients who had ESPB, only 4 had minor neurological findings and no significant complication rate was found. There was zero percent complication rate in another study, where ESPB was performed in 342 patients (22). The only complication we

faced was accidental catheter pull-out in 10 cases (13.1%) and 1 (1.3%) of patients who had leakage from the catheter site.

The limitation of our study is its retrospective nature and the missing record of a few patients. The follow-up of patients was limited to their in-patient stay. We hope that our research will help improve ESPB analgesia practice in the future.

Conclusion

Erector Spinae Plane Block provides the best pain relief with minimum complication risks and maximum postoperative benefits, including its use in patients with coagulopathy and systemic infections. So, ESPB catheter-based analgesia with continuous infusion (0.15 or 0.2% bupivacaine at 15-20ml/hour) should be the preferred mode of postoperative analgesia after thoracic surgery. The catheter can be kept for a maximum of 6 days. Hence, a collaborative approach is required between the thoracic surgeon and the anesthetist.

Declarations

Data Availability statement

All data generated or analysed during the study are included in the manuscript.

Ethics approval and consent to participate

Approved by the department concerned. (IRBEC-MMNCS-0331d-24)

Consent for publication

Approved

Funding

Not applicable

Conflict of interest

The authors declared the absence of a conflict of interest.

Author Contribution

SUR

Manuscript drafting, Study Design,

NQ

Review of Literature, Data entry, Data analysis, and drafting article.

AK Conception of Study, Development of Research Methodology Design,

RB

Study Design, manuscript review, critical input.

US

Manuscript drafting, Study Design,

ER

Review of Literature, Data entry, Data analysis, and drafting article.

All authors reviewed the results and approved the final version of the manuscript. They are also accountable for the integrity of the study.

References

1. Kot P, Rodriguez P, Granell M, et al. Continuous erector spinae plane block for thoracic surgery: a randomised controlled trial. *Eur J Anaesthesiol.* 2021; 38(9):980-988. DOI: 10.1097/EJA.0000000000001441
2. López-Romero JL, González-Pérez F, León-Justel A, et al. Ultrasound-guided continuous erector spinae plane block for perioperative analgesia in breast surgery: A randomised, controlled clinical trial. *J Clin Anesth.* 2021; 75:110458. DOI: 10.1016/j.jclinane.2021.110458
3. Adhikary SD, Pruet A, Forero M, et al. Erector Spinae Plane Block as an Alternative to Epidural Analgesia for Postoperative Analgesia Following Video-Assisted Thoracoscopic Surgery: A Case Study and a Literature Review on the Spread of Local Anesthetic in the Erector Spinae Plane. *Int J Surg Case Rep.* 2018; 51:41-45. DOI: 10.1016/j.ijscr.2018.08.068.
4. Adhikary SD, Prasad A, Soleimani B et al (2019) Continuous erector spinae plane block as an effective analgesic option in anticoagulated patients after left ventricular assist device implantation: a case series. *J Cardiothorac Vasc Anesth* 33(4):1063–1067
5. Alissa Greenbaum, Hannah Wilcox, Christine H. Teng, Timothy Petersen, Mary Billstrand, Rachel Campbell, Nichole Bordegaray, Itzhak Nir, Use of Erector Spinae Fascial Plane Blocks in Enhanced Recovery for Open Abdominal Surgery, *Journal of Surgical Research*, Volume 268,2021, Pages 673-680, ISSN 0022-4804, <https://doi.org/10.1016/j.jss.2021.08.008>
6. Zhang B, Ochuba AJ, Mullen GR, Rai A, Aro T, Hoeng DM, Okeke Z, Winoker JS. How I Do It: ERAS protocol featuring erector spinae plane block for percutaneous nephrolithotomy. *Can J Urol.* 2023 Aug; 30(4):11639-11643. PMID: 37633294.
7. Forero M, Adhikary SD, Lopez H, et al. The Erector Spinae Plane Block: A Novel Analgesic Technique in Thoracic Neuropathic Pain. *Reg Anesth Pain Med.* 2016; 41(5):621-627. DOI: 10.1097/AAP.0000000000000451
8. Blanco R, Parras T, McDonnell JG, et al. Serratus plane block: a novel ultrasound-guided thoracic wall nerve block. *Anaesthesia.* 2013; 68(11):1107-1113. DOI: 10.1111/anae.12344
1. Kot P, Rodriguez P, Granell M, et al. Continuous erector spinae plane block for thoracic surgery: a randomised controlled trial. *Eur J Anaesthesiol.* 2021; 38(9):980-988. DOI: 10.1097/EJA.0000000000001441
9. Aksu C, Kus A, Yorukoglu HU, Tor Kilic C, Gurkan Y. Analgesic effect of the bi-level injection erector spinae plane block after breast surgery: a randomised controlled trial. *Agri.* 2019; 31:132–137. (PubMed) (Google Scholar)
10. Ibrahim M, Elnabtity AM. Analgesic efficacy of erector spinae plane block in percutaneous nephrolithotomy: a randomised controlled trial. *Anaesthesist.* 2019; 68:755–761. Doi: 10.1007/s00101-019-00673-w. (PubMed) (CrossRef) (Google Scholar)
11. Yao Y, Li H, He Q, Chen T, Wang Y, Zheng X. Efficacy of ultrasound-guided erector spinae plane block on postoperative quality of recovery and analgesia after modified radical mastectomy: randomised controlled trial. *Reg Anesth Pain Med.* 2019. (PubMed)
12. Chakraborty A, Khanna P, Dhulkhed V, et al. Comparison of ultrasound-guided thoracic paravertebral block and erector spinae plane block in video-assisted thoracoscopic surgery: A randomised controlled trial. *Indian J Anaesth.* 2021; 65(9):737-744. DOI: 10.4103/ija.IJA_1720_20
13. Benjamin D, Zoubir D, Fairuz B, Emmanuel B, and Francois M, Jean Marc B et al. Erector Spinae Plane Block versus Paravertebral block after thoracic surgery for lung cancer: A Propensity score study. *Cancers* 2023, 15(8), 2306; <https://doi.org/10.3390/cancers15082306>
14. Yang, H.-M.; Choi, Y.J.; Kwon, H.-J.; O, J.; Cho, T.H.; Kim, S.H. Comparison of Injectate Spread and Nerve Involvement between Retrolaminar and Erector Spinae Plane Blocks in the Thoracic Region: A Cadaveric Study. *Anaesthesia* 2018, 73, 1244–1250.
15. Chin KJ, El-Boghdady K. Mechanisms of action of the erector spinae plane (ESP) block: A narrative review. *Can J Anaesth.* 2021; 68:387–408.
16. Adhikary SD, Prasad A, Soleimani B, Chin KJ. Continuous Erector Spinae Plane Block as an Effective Analgesic Option in Anticoagulated Patients after Left Ventricular Assist Device Implantation: A Case Series. *J Cardiothorac Vasc Anesth.* 2019 Apr; 33(4):1063-1067. doi: 10.1053/j.jvca.2018.04.026. Epub 2018 Apr 12. PMID: 29753668.
17. Horlocker TT, Vandermeulen E, Kopp SL, Gogarten W, Leftert LR, Benzon HT. Regional Anesthesia in the Patient Receiving Antithrombotic or Thrombolytic Therapy: American Society of Regional Anesthesia and Pain Medicine Evidence-Based Guidelines (Fourth Edition). *Reg Anesth Pain Med.* 2018 Apr; 43(3):263-309. Doi: 10.1097/AAP.0000000000000763. Erratum in: *Reg Anesth Pain Med.* 2018 Jul; 43(5):566. Doi: 10.1097/AAP.0000000000000807. Vandermeulen, Erik (corrected to Vandermeulen, Erik). PMID: 29561531.
18. Thamizharasan Datchinamourthy, Debesh Bhoi, Anjolie Chhabra, Virender K. Mohan, Kanil R. Kumar, and Poornima Ranganathan. Comparative evaluation of continuous infusion versus programmed intermittent bolus techniques in erector spinae plane block in modified radical mastectomy – A preliminary randomised controlled trial. *Indian J Anaesth.* 2024 Mar; 68(3): 273–279. Published online 2024 Feb 22. doi: 10.4103/ija.ija_922_23.
19. Tulgar S, Selvi O, Ozer Z. Clinical experience of ultrasound-guided single and bi-level erector spinae plane block for postoperative analgesia in patients undergoing thoracotomy. *J Clin Anesth.* 2018 Nov; 50:22-23. Doi: 10.1016/j.jclinane.2018.06.034. Epub 2018 Jun 23. PMID: 29940470.
20. De Cassai A, Tonetti T. Local anesthetic spread during erector spinae plane block. *J Clin Anesth.* 2018 Aug; 48:60-61. doi: 10.1016/j.jclinane.2018.05.003. Epub 2018 May 10. PMID: 29753992.
21. S. Tulgot, O. Telvi, DT Thomas and Z Ozer. Erector Spinae block in 308 patients: complications and unexpected events. *Regional Anaesthesia and Pain Medicine* 2019; 44, A112.
22. Oezel L, Hughes AP, Onyekwere I et al. Procedure-Specific Complications Associated with Ultrasound-Guided Erector Spinae Plane Block for Lumbar Spine Surgery: A Retrospective Analysis of 342 Consecutive Cases. *J Pain Res.* 2022; 15: 655–661. Published online 2022 Mar 3. Doi: 10.2147/JPR.S354111.



Open Access This article is licensed under a Creative Commons Attribution 4.0 International License, <http://creativecommons.org/licenses/by/4.0/>. © The Author(s) 2025